

*Veterinary Surgical Services
215 Center Park Drive
Knoxville, TN 37922
(865) 966-3920*

OPERATIVE REPORT

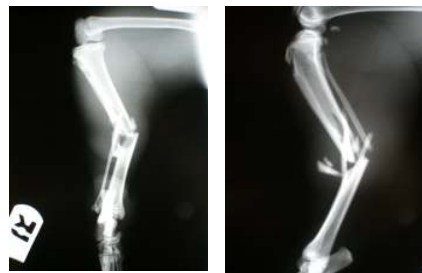Case No : 9010

Ref Vet: Jackson

Patient: Munchkin

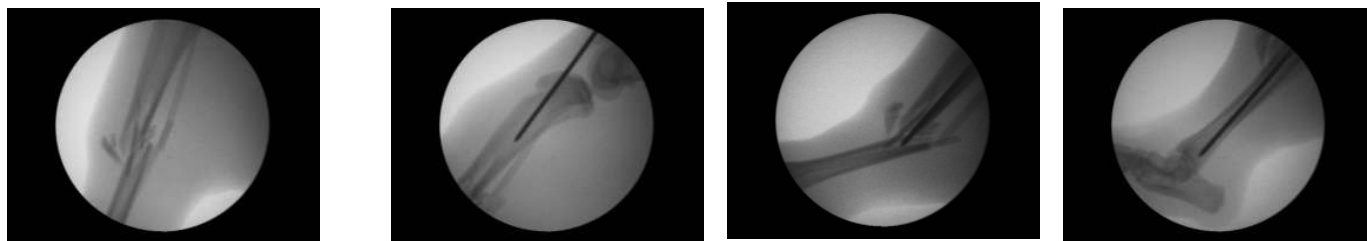
Date: 5-5-06

Pre Op Dx: Comminuted diaphyseal fracture of the right tibia. Multiple splinter fragments are present.

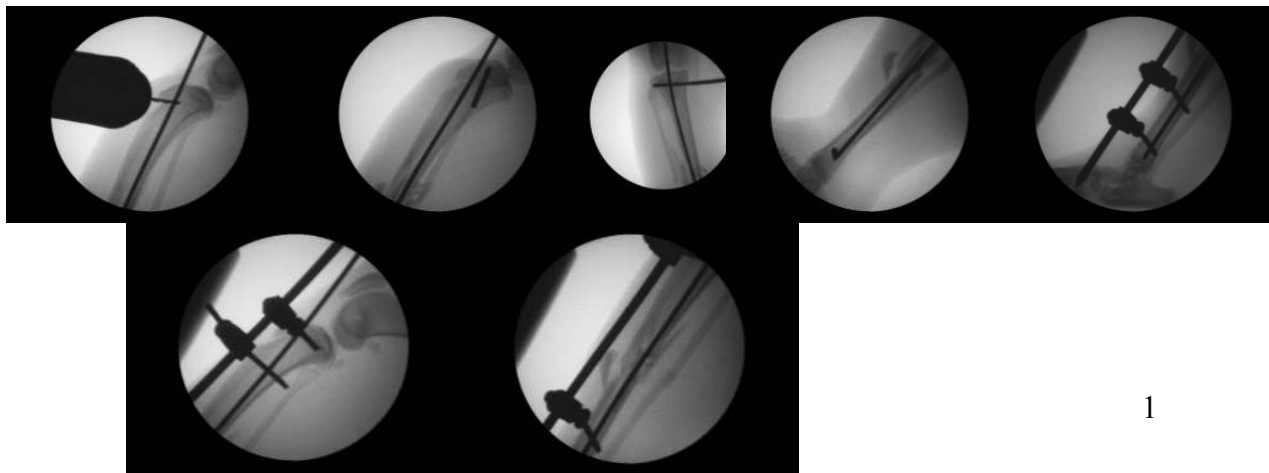


Pre-Op Notes: See Er Report. Metacam 1 mg sq. Masked down with Iso > Main.

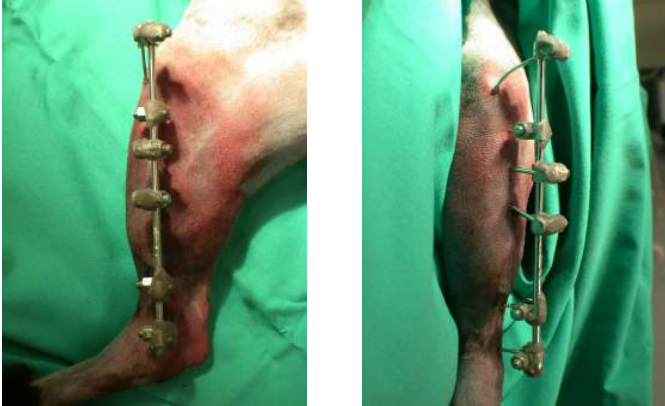
Operation in Detail: The right leg was cleaned and prepped for surgery. There was extensive bruising and pitting edema. Due to the extensive bruising and splintered frags, a closed reduction is indicated. The cat was placed in right lateral recumbency. The entire cat was draped so only the right rear leg was exposed in the field. Under Fluoroscopic guidance, a 5/64 IM pin was inserted normo-grade from the dorso-medial side of the tibia down the proximal shaft. Next, the distal seg was held in alignment under fluoro, and the IM pin was inserted distally.



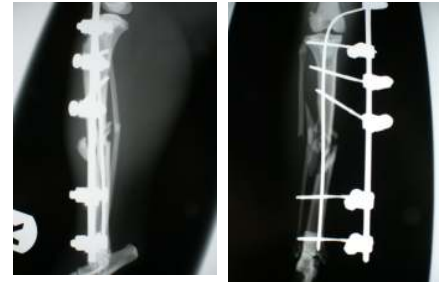
A 2.7mm external fixation pin was inserted in the most proximal and distal segments of the tibia. A rod with 3 additional clamps was mounted to the ext fix pins with the tibia held in alignment. Two additional Ext Fix pins were placed in the prox seg followed by one additional in the distal segment. The clamps were applied and all were tightened. Alignment looked good under fluoro.



All clamps were tightened and pins filed smooth. An acrylic was applied to cut down on scratching his surroundings. The IM pin was bent and mounted to the ext rod as well.



Post Operative Notes. Rads show good alignment and fixation.



Post Operative Instructions:

No Running , jumping or stairs. STRICT confinement. Follow instructions as provided. Keep away from slippery surfaces. Give antibiotics and pain meds as directed. Re-check in 4weeks. Then, Follow-up X-ray at 8 weeks and at 12 weeks.

Clean around pins with warm water. You can apply some Neosporin ointment to the holes daily, but make sure you keep them clean. There will be additional costs for removal of the ext fixator. It may need to be removed in stages depending on the amount of healing at 8 weeks. The clamps must be returned when finished, or you will be billed \$300.00 for their cost if not returned.

Please call if you have any questions or problems.
Mitch Rosenzweig, DVM